Evoked responses, Contrast imaging techniques and outcomes in Infraclavicular Blocks.

Sandeep Diwan[1]

Abstract

The infracalvicular brachial plexus block are indicated for the below elbow surgeries and are one of the commonly used blocks. This article presents a review of outcomes of infraclavicular blocks with focus on anatomical dissection and imaging studies

Keywords: infraclavicular blocks, anatomy, contrast studies

Introduction

The coracoid infraclavicular1 technique, originally described by Whifflerin 1981, has become popular because of relatively easily identified anatomic landmarks, reliable distribution of neural blockade, and low risk of respiratory complications, such as phrenic nerve blockade and pneumothorax [1].

The anatomic surface landmarks are easy to identify, the head and arm may be in any position for the block, the technique is relatively easy to perform using either a nervestimulator or ultrasound guidance.

The sheath over the brachial cords are exposed (Fig 1). Around the axillary artery the brachial cords are tightly held together (Fig 2). The lateral cord has a definitive position at around 10-11 'o' clock position and is superficial, the posterior cord is usually located at the 6 'o' clock position but can vary its position anywhere from 3-8 '0' clock. The medial cord is said to be sandwitched between the axillary artery and the vein and can again lie from 2-7 '0'clock position.

The brachial cords formation :

- The anterior divisions of the superior and middle trunks forms the lateral cord.
- The posterior divisions of all 3 trunks forms the posterior cord, and
- The anterior division of the inferior trunk forms the medial cord.

The cords are according to their relationship to the axillary artery as mentioned earlier.

In a sagittal plane (Fig 3) the cords are visualized around the axillary artery. The lateral cord is situated just below the pectoralis minor. The medial cord shown in this image is caudal to the artery while the posterior cord is caudal and still further away from the artery.

The existence of the cords can vary and are situated at various locations as suggested by these two important studies (Fig 3).

In the mid-infraclavicular area [2], the lateral cord always lay anterior to the posterior or medial cord and cranial to the axillary artery; the posterior cord was always cranial to the medial cord, both cords were always located dorsal to the artery.

Sauter et al [3] mentioned the placement of the cords at 2cm from the centre of the axillary artery. Analysis of MRI data in the sagittal plane of the LSIB demonstrated that the cords were found within 2 cm from the center of the artery approximately within 2/3 of a circle. The cords were distributed between III and XI o'clock.

Technique : Vertical infraclavicular

The author uses the Wilsons [4] approach to the infraclavicular brachial plexus. The entry point of the needle lies 2 cm medial and 2 cm inferior to the coracoid process.

The patient lies supine with the head turned away from the arm to be anesthetized.

The arm lies parallel to the trunk (adducted) and or is allowed to rest comfortably on the abdomen. This is particularly necessary in patients with forearm and elbow injuries.

The point of puncture is 2 cm medial and 2 cm inferior to the lateral tip of the coracoid process.

The needle is inserted 2cm medial and inferior to the coracoid process (Fig 4)

The needle penetrates through the pectoralis major and minor.

A pop is felt as the needle tip penetrates through the pectoralis major and another pop as it goes through the pectoralis minor.

End points for neuro stimulation in Infraclavicular block.

Extension of the wrist and or the extension of the fingers – suggests posterior cord stimulation.

Flexion of wrist and or the flexion of the fingers- suggests medial cord stimulation.

The PNS is fine tuned at 0.3ma to produce the same response as mentioned earlier.

The needle is then held firmly and after aspiration and after an initial injection by the performer the syringe is handed over to the assistant to inject the drug.

[1]Department of Anaesthesiology, Sancheti Institute for Orthopaedics and Rehablitation, Pune, India.

Address of Correspondence
Dr Sandeep Diwan
Department of Anaesthesiology, Sancheti Institute for Orthopaedics and Rehablitation, Pune, India.
Email: sdiwan14@gmail.com

Dr. Sandeep Diwan

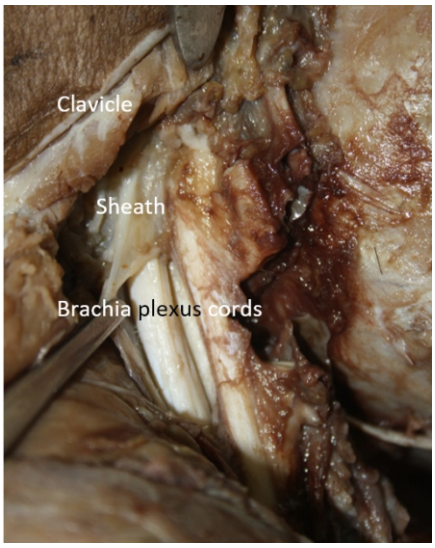

Figure 1: Infraclavicular cords engulfed in a sheath

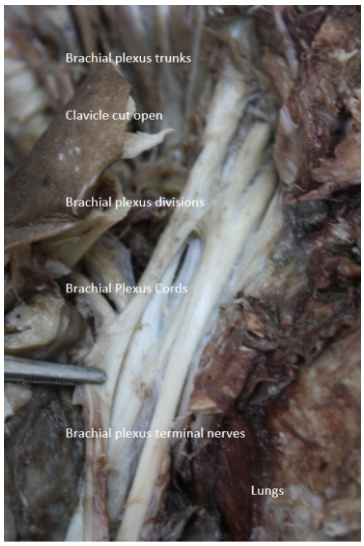

Figure 2: The brachial plexus outlay

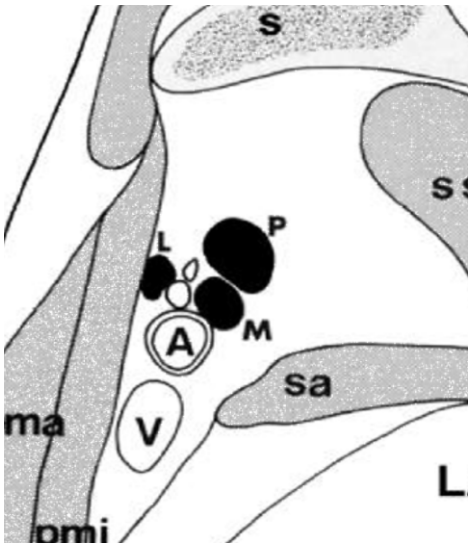

Figure 3: Sagittal section depicting the probable cord placements in the infraclavicular area.

Volume of drug :
30 ml of 0.5 % bupivacaine (20ml) and 1.5% xylocaine (10ml) with adrenaline for prolonged procedures.
Note: It is important to note the tissue pressures during injection. Hence it is more appropriate for the anesthesiologist to inject initially. The syringe is then handed over to the assistant.

Neurostimulation induced evoked muscle responses –

Posterior cord neurostimulation.
Alain Borgeatet al[7] reported a 97% rate of infraclavicular block success when nerve stimulation elicited a distal response. Harish Lecamwasamet al[5] report in their study that stimulation of the posterior cord predicts successful infraclavicular block. Failure rates were 5.8% for posterior cord, 28.3% for lateral cord, and 15.4% for medial cord responses.
The posterior cord appears to lie central to both the lateral and medial cords [6]. A "central" location is considered because the relative positions of the cords change as they twist around the axillary artery [6].

Why not a medial cord response?
The median nerve is formed from dual contributions - median nerve from both medial and lateral cords. Hence identifying distal flexion responses as the target response may not be specific.
Wrist flexion [8,9] can be achieved by needle stimulation in four different positions in the plexus:

- the lateral cord, (pronator teres fibers and flexor carpi radialis)
- the lateral root of the median nerve, (flexor carpi radialis and palmarislongus)
- the medial cord, (flexor digitorumprofundus, flexor pollicislongus, and intrinsic thenar)
- the medial root of the median nerve, (flexor carpi ulnaris and flexor digitorum sublimus)

Optimal evoked muscle response:
The ideal response is a posterior cord [10] response with a success rate of 96% followed by a median nerve response with a success rate of 89% with 40ml of 1.5% lignocaine.
A study [11] compared the outcome of single, dual and triple nerve neurostimulation infraclavicular block. The authors conclude that the outcome with dual injection infraclavicular coracoid block was better than a single-injection technique in providing anesthesia of the upper limb
In three Randomised Controlled Trials [12,13,14] (totaling 215 patients), a multiple-stimulation technique consistently produced better sensory and motor blockade at 20 min in the musculocutaneous, ulnar and radial territories. This was associated with increased patient satisfaction and an overall success rate of 72.5% (compared to 40% for a single-injection technique).
Multiple injections [15] may allow a 25% decrease in the volume of local anesthetics (from 40 to 30 mL) without affecting the quality of the block.

Drug volume and concentration and the outcome.
A 40 mL fixed volume and variable concentration of local anesthetic mixture was administered via a modified coracoid approach to the infraclavicular brachial plexus using a double-stimulation technique [16]. Comparisons between different concentrations of bupivacaine and lidocaine were performed , it was observed that 1.5% plain lidocaine and 0.37% bupivacaine with epinephrine 1:200,000 provided the best results. There were no block failures and tourniquet tolerance was the adequate with this regimen.
In this authors extensive study of over 5000 infraclavicular block (1994 – 2017 unpublished) the following concentrations and volumes of local anesthetics were used with a single response either a posterior cord (preferentially) or a medial cord response was obtained, and, following volumes were injected. The drug was injected on obtaining the first response (either the posterior or the medial).
On obtaining the response 5ml of contrast was injected(Omnipaque 300mg I /ml), following which the entire volume was injected. The contrast images were retrieved and analysed further for the spread in the infraclavicular sheath.

Volume of L A following a Posterior Cord response
30ml, 1.5% Xylocaine 10ml and 0.5% Bupivacaine 20ml for prolonged procedures.

Volume of L A following a Median nerve response.

Figure 4: Anatomical landmarks for infraclavicular block Coracoid process – dark yellow Needle insertion – 2cm medial (blue) and inferior (blue) to the coracoid process

40ml, 1.5% Xylocaine 10ml and 0.5% Bupivacaine 30ml for prolonged procedures. The images depicted below are few samples from the extensive study performed by this author on the spread of the contrast after

a. Posterior cord stimulation.

b. Medial cord Stimulation.

Posterior cord stimulation and contrast studies.

A posterior cord response was obtained with needle directed vertically into the infraclavicular fossa, 2cm medial and 2 cm inferior to the coracoid process.

The posterior cord stimulation evokes extension of the metacarpophalangeal and the wrist joints at 0.4mA.

A 1 ml contrast was injected following which images was obtained (Fig 5). Serial images were then retrieved after 1ml contrast followed by 5ml local anesthetic and finally a 30ml local anesthetic agent. As the contrast is injected a more cephalad spread is identified towards the retroclavicular area where the divisions of brachial plexus exists (Fig 6)

With around 20ml of volume of local anesthetic the contrast delineates the sheath of the cord and extends to the divisions of brachial plexus in the supraclavicular area (Fig 7).

Increasing the volume of the local anesthetic injected in the infraclavicular area after a posterior cord stimulation increases the spread cephalad towards the supraclavicular area. Note the linear rail track appearance (green – cervical spread, yellow arrow – needle position, red – axillary spread) from the point of injection cephalad to the retroclavicular area (Fig 7).

The needle is vertical and posterior cord stimulation was evoked at 0.4Ma(Fig 8).

Initially 1ml contrast was injected revealed a craniocaudad spread(red double arrow). As more local anesthetic was injected a cranial spread in the retroclavicular area was visualized at 5 ml and with further administration of 25ml of local anesthetic and 2ml contrast the spread (Fig 9) was significant in the cervical root are (violet arrow) .

The contrast spread reveals extensive spread across the perineural sheath from the level of the cervical roots through the supraclavicular, retroclavicular, infraclavicular and distal into the axilla.

Note the distance the drug with contrast has travelled cephalad (Fig 8 and Fig 9) The lung is displayed as light pink (Fig 9) and is comfortably situated away from the needle tip. It is astonishing to observe the spread of the contrast with 30 ml of local anesthetic, the volume which is routinely injected in the neurostimulation guided infraclavicular brachial plexus block almost reaching the cervical roots (violet arrow) (Fig 9) . This particularly occurred with the posterior cord stimulation where a cephalad spread of the drug was observed.

Literature.

Rodríguez Jet al [14] compare the efficacy of multiple injection and single posterior cord injection techniques in terms of the rates of completely anesthetizing cutaneous nerves below the elbow. They confirmed that the injection of a local anesthetic after a single stimulation of the posterior cord

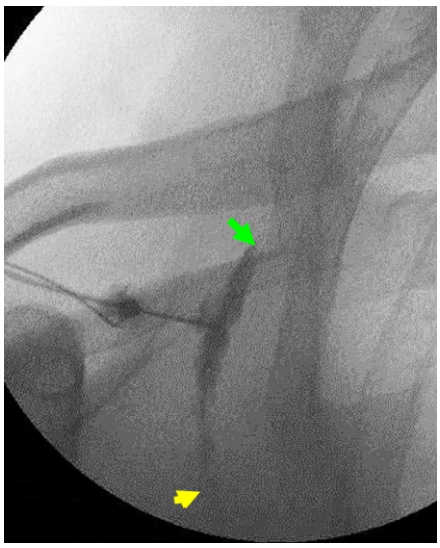

Figure 5: Contrast spread cephalad and caudad to the needle tip after a posterior cord stimulation.

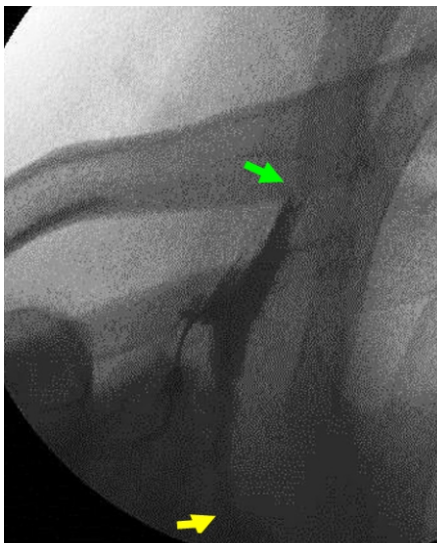

Figure 6: The spread is more towards the clavicle. Imaging Diwan Sandeep 2013

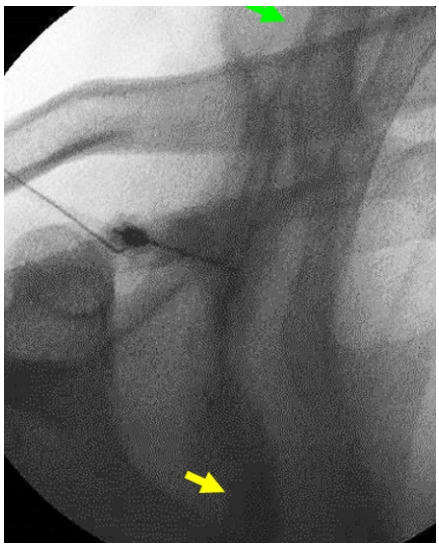

Figure 7: The increase in volume leads to an increased spread more towards the supraclavicular brachial plexus divisions.

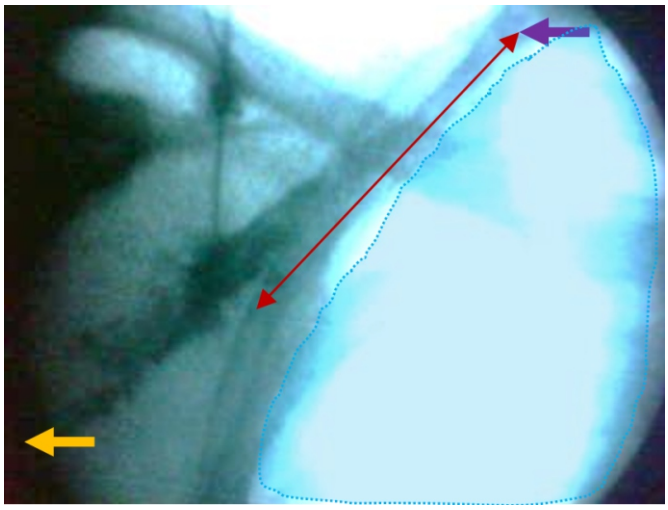

Figure 8: Needle in infraclavicular area : Posterior cord stimulationat 0.4mA

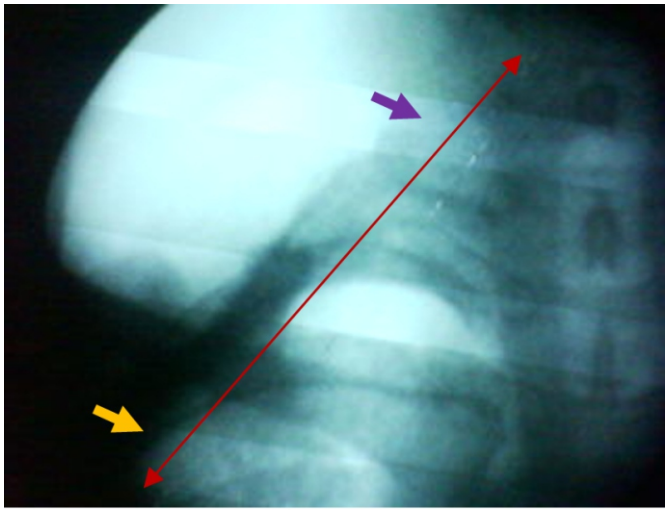

Figure 9: A total of 30ml of LA lead to further spread almost towards the cervical roots (pink).

fibers produced more extensive anesthesia than using a dual stimulation technique.
Bloc S et al17compared the success rate of single-injection infraclavicular plexus block by using electrically evoked radial, ulnar, or median nerve-type distal motor response. With a current less than 0.5Ma, the distal motor response was evoked without aiming for a definitive response. 30ml of 1.5% mepivacaine was injected. They observed that the success rate of the infraclavicular plexus block was significantly higher when the injection was performed on a radial nerve-type response (90%) as compared with the median (74%) or ulnar (68%) nerve distal motor response. The highest success rate was obtained when injection was performed after radial nerve type motor response.
Outcome: The anesthesia and analgesia was excellent in the distribution of the radial, median and ulnar nerves and suited for the surgeries on the elbow, forearm and wrist.Thus the studies mentioned earlier quote the importance of the posterior cord stimulation and its association with a denser block could well be correlated with the cephalad spread of the drug as observed by this author with the contrast studies. The cephalad spread effectively blocks the musculocutaneous, axillary and the medial cutaneous nerves of the arm and forearm and the posterior cutaneous nerve of the arm.

Medial cord stimulation and contrast studies.

A medial cord response was obtained with needle directed vertically into the infraclavicular fossa, 2cm medial and 2 cm inferior to the coracoid process.
The medial cord stimulation evokes flexion of the metacarpophalangeal and the wrist joints at 0.4mA.
A 1 ml contrast was injected as specified earlier. Serial images were obtained after 1ml contrast followed by 5ml local anesthetic and finally a 20ml local anesthetic agent.
Another 1 ml of contrast was injected and 5ml of 0.5% bupivacaine was injected. As the contrast is injected a more caudad spread is identified towards the axillary area where the terminal nerves exists (Fig 10)
Thus it was a common observation that a medial cord stimulation leads to extensive spread more distally into the axillary area than proximally into the retroclavicular area. As visualised in the image below distal spread in the axillary area is more than the proximal spread(Fig 10 and 11).
In stark contrast to posterior cord stimulation the medial cord stimulation produces a more distal spread and beyond the level of the axillary tail (yellow arrows) (Fig 10, 11). A slight proximal spread is observed but not in the retroclavicular area

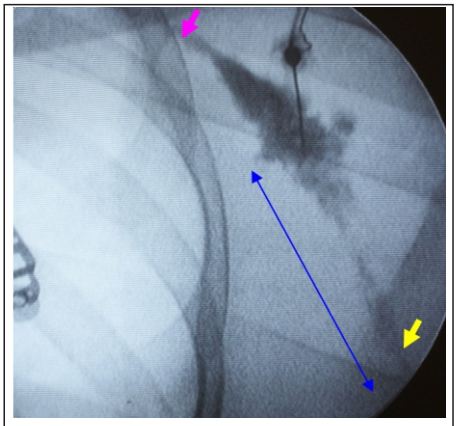

Figure 10: Medial cord stimulation at 0.4Ma and the distal spread

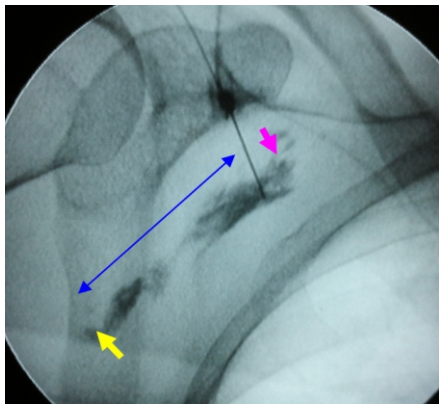

Figure 11: This image shows more distal spread after medial cord stimulation at 0.4Ma.

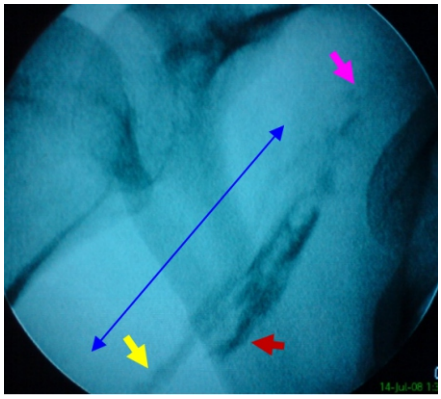

Figure 12: The contrast spreads more distally after a medial cord stimulation.

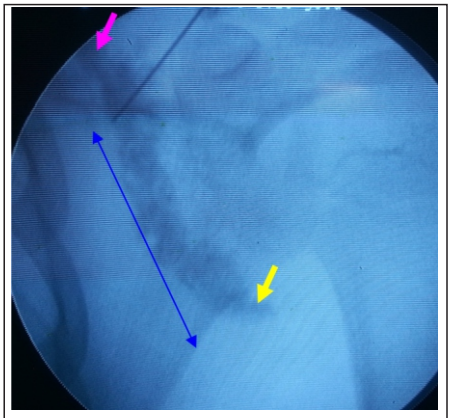

Figure 13: Contrast flows distally across the perineural sheath after medial cord response at 0.4Ma.

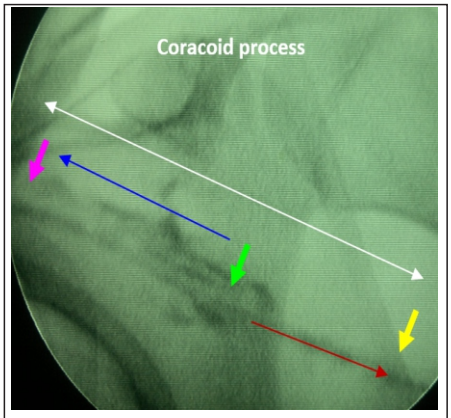

Figure 14: Contrast flows distally across the perineural sheath after medial cord response at 0.4Ma.

(pink) (Fig 10). A fusiform dilatation is seen in the infraclavicular area suggesting that this area is highly compliant (Fig 10). Note that the needle is exactly in mid of the sheath (Fig10) and the distance the contrast has traveled distally (Fig 10).
The needle orientation is medial and caudad (Fig 11) The injected contrast spreads for a short distance (pink) proximally, distally there a discontinuity at one point with a slender thin spread medially (red) followed by a more denser distal spread (yellow) (Fig 11). The needle seems to be close to the exit of the sheath. A small displacement of the needle tip and it will lie outside the sheath (Fig 11).
The contrast image depicting the distal spread after a medial cord stimulation (Fig 12) while the contrast image (Fig 13) displays an unusual thick brand of contrast at the point of needle insertion. Though there is proximal small spread (pink) the distal spread (yellow) is significant as the drug spreads in the axillary sheath. Note the uniform and linear spread (Fig 13) of the contrast distal to the needle tip with a medial cord response 0.4Ma.
Thus it is a common observation that with a medial cord response the spread is more distally into the axillary sheath.
Outcome: The anesthesia and analgesia was excellent in the distribution of the median and ulnar nerves and suited for the surgeries on the forearm and wrist. The posterior cutaneous nerve of arm was spared in almost all the cases. The musculocutaneous and axillary nerves remained partially blocked.
To overcome this, author injected 10ml of extra volume after a medial cord stimulation i.e a total volume of 40ml. It was then observed that after increasing the volume from 30ml – 40ml the posterior cutaneous nerve of arm and the lateral antebrachial cutaneous nerve of forearm (cutaneous branch of the musculocutaneous nerve) were adequately blocked.

Multicompartment infraclavicular space
The needle insertion is 2 cm medial and inferior to the coracoid process. Initially either a medial or a posterior cord response was obtained, after injecting 1ml of contrast images were obtained, the second response was elicited (posterior or medial cord) and after injecting 1 ml of contrast images were downloaded.
The contrast spread (Fig 14) distally with the medial cord response and proximally with the posterior cord response. The entire spread from the costoclavicular area distal to the axillary area can be delineated. After the later cord response (either the posterior or the medial) the entire volume of local anesthetic was injected. Note that at the point of injection (green) the spread after the medial cord response is in a separate distal compartment (maroon) as against the spread in the proximal compartment (blue) after a posterior cord response.
There is spread from the needle insertion site (green) (Fig 15, 16) which is broad band (blue) followed by a thin slender spread in the axillary sheath (maroon). The distal flow (Fig 16) probably could be in the median nerve sheath.
The contrast was injected once the posterior cord was identified at 0.4Ma(Fig 15). The contrast spread proximally upto the retroclavicular area (blue). A thin contrast spread is visualized distally (maroon) (Fig 16) in the axilla.
As the volume of the drug is increased the contrast and the drug spreads in the medial compartment yellow) (Fig 16).The medial contrast spread is in fact retrograde from the point of needle tip location (yellow in Fig 16). The retrograde extension is as far as the retroclavicular area (Fig 16).
This suggests that the compartments are interconnected and open up at slightly

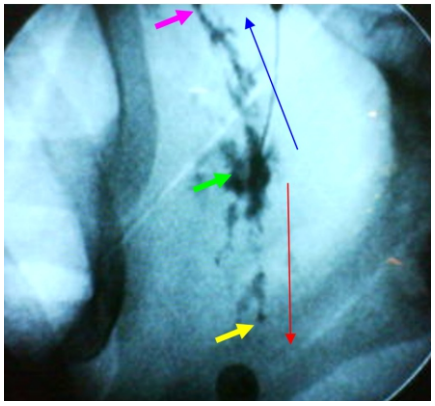

Figure 15: Posterior cord response and contrast spread.

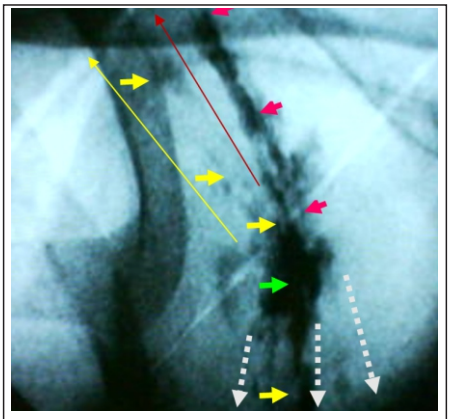

Figure 16: Retrograde filling of the medial most compartment as the contrast and drug volume increase.

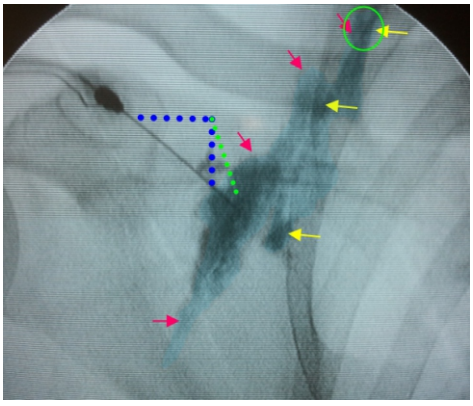

Figure 17: Needle angulation and tip identification.

Figure 18: Contrast in interscalene area.



Figure 19: Contrast over the first rib.

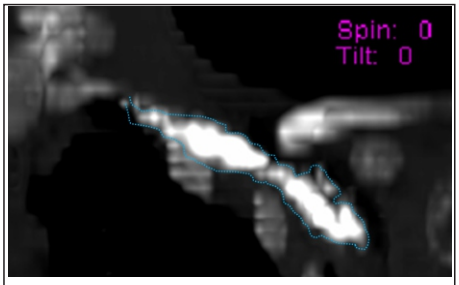

Figure 20: Contrast extension along the brachial sheath (blue dotted).

higher pressures.

The efficacy and outcome of single neurostimulation is equivalent to multineurostimulation infraclavicular block [12,14 18]. In this authors study, a single neurostimulation either the posterior cord or the medial cord at 0.4Ma was obtained and 30ml of 0.5% bupivacaine (20ml) and 1.5% xyloacaine (10 ml) was injected. It was a common observation on contrast injection , the spread was cephalad, with posterior cord stimulation and blocking all the nerves (median, radial, ulnar, musculocutaneous, axillary and medial cutaneous nerves of arm and forearm). The blockade of the musculocutaneous axillary and medial cutaneous nerves of arm and forearm were significantly with the medial cord stimulation and the contrast spread was more distal and caudad with the medial cord stimulation. It is a general notion and there is no clear anatomic basis in literature to explain that distal stimulation is associated with better success [19]. Musculocutaneous might egress proximally and a stimulation and injection at this neurosite will not soak the other two cords [20,21]. It is a general belief that after obtaining a distal response, the needle is more centrally placed, resulting in even diffusion of local anaesthetic [5, 20 21].

This contrast study proves that a single neurostimulation of the posterior will deposit the drug in the centre of the brachial plexus with a more linear cephalad spread than the caudad. With the medial cord stimulation a more caudad spread is observed.

The efficacy of the block is also better with the posterior cord stimulation.

Supraclavicular extension of infraclavicular contrast.

Needle tip reorientation.

It is a common occurrence that with the vertical needle placement 2cm medial and 2 cm inferior to the coracoid process, more than 50% of times encounters the lateral cord. It is only at times one comes across either the posterior cord or the medial cord at the first pass.

In reference to image (Fig 17) once the lateral cord is encountered, a slight needle tip deviation is required to elicit the posterior cord or the medial cord responses. This authors makes small shifts of 5 degrees angle cephalad, caudad, medial and lateral , once the lateral cord responses are evoked. Note the angulation (from blue to green) of the needle tip to elicit posterior cord response after its vertical placement had obtained a lateral cord response.

Note the contrast spreads across the posterior cord cephalad in the supraclavicular area (pink). As we move caudad the contrast spreads medially (yellow).

CT Contrast study of Infraclavicular block with posterior cord identification.

A vertical needle placement in the infraclavicular fossa 2cm medial and 2 cm inferior to the coracoid process identified the posterior cord. 5ml contrast and 15ml of 0.5% bupivacaine was injected. Serial CT Scan images were performed and images were analysed. The images were analysed from the cervical area and followed caudad to the infraclavicular area. The contrast appeared in the lower interscalene area (green) sandwiched between the anterior and middle scalene muscle (Fig 18). The perineural sheath engulfing the brachial plexus can be delineated till the costoclavicular area (dark yellow) (Fig 18). As the contrast spread was observed in the supraclavicualar area (Fig 19) a fusiform dilatation of the contrast overlying the first rib denoting the compliance and compactness of the supraclavicular space (blue dotted) (Fig 19) is spotted. There is a

Figure 21: Axillary spread of contrast.

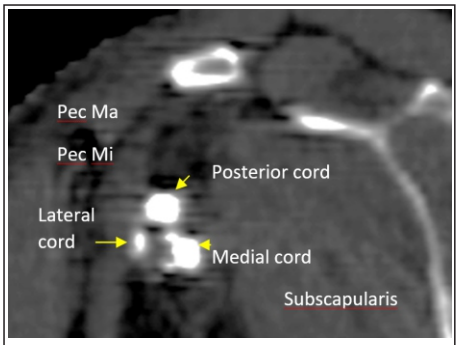

Figure 22: Single Posterior cord neurostimulation depicting the spread across all three cords.

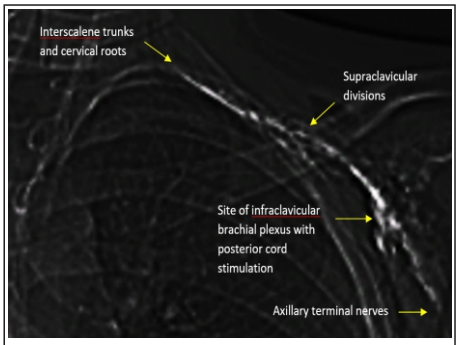

Figure 23: The entire brachial plexus delineated with single neurostimulation approach of infraclavicular block. The cervical roots, the brachial trunks, cords and terminal nerve are depicted.

gradual increase in the width of the contrast, descending from the interscalene to the supraclavicular area.

The next image (Fig. 20) depicts the supraclavicular spread across the first rib and more infraclavicular spread over the second and the third rib. The spread is medial to the coracoid process and at the proposed point 2cm medial and 2cm inferior to the coracoid process. The proximal spread is observed in the costoclavicular, retroclavicular and supraclavicular area.

The contrast is bounded by the rib, the clavicle, the thoracic cavity and the head shaft humerus. The extension of the contrast is now clearly depicted as it flows across the sheath that engulfs the of subclavian perivascular, the infraclavicular and to proximal part of the axillary area(Fig 20).

The axillary spread is longitudinal along the axillary sheath.(Fig 21). It shows a beaded appearance as the contrast spreads exactly along the mid portion of thoracic cavity and the scapula laterally. The sagittal image (Fig 22) visualizes the spread of contrast across all three cords with a single neurostimulation technique, thus establishing the fact that single neurostimulation would be equivalent to multineurostimulation. In fact this is the authors concern that with the proposed multineurostimulation in the infraclavicular technique the incidence of nerve injuries, vascular and pleural punctures would be on higher side than with the single neurostimulation technique targeting the posterior cord or the medial cord.

Literature.

Rodríguez J el al [22] compared the distribution of local anesthetic within the neurovascular space in infraclavicular block with that of interscalene and supraclavicular block. They performed fluoroscopy guided radiocontrast studies and observed the spread in interscalene, supraclavicular and the infraclavicular blocks. They observed that the distribution of the anesthetic solution in the interscalene and supraclavicular groups extended to both supraclavicular and infraclavicular spaces in all patients. In the infraclavicular group the solution remained below the clavicle in every patient.

They conclude that spread of the local anesthetic solution after infraclavicular block is restricted to below the clavicle.

Bloc S et al [23] in thirty two patients compared characteristics of spread during ultrasound infraclavicular brachial-plexus blocks by use of electrically evoked radial nerve or median nerve type distal motor responses to guide the injection of 30 mL of 1.5% mepivacaine. They observed that with the radial nerve type motor response, the success rate of infraclavicular plexus block was 100%. As opposed to this three supplemental axillary blocks were administered with median nerve type motor response.

They did not inject contrast though they mention that the quality diffusion scores were significantly higher with radial nerve type as compared with median nerve type motor response.

The ultrasound spread was characteristic

- Radial nerve response was : Posterior local anesthetic spread associated with medial and upper movement of the axillary artery.
- Median nerve response : Specific posterior displacement of the axillary artery that resulted from superficial spread.

Bloc S demonstrated that as compared with median nerve type motor response, injection performed after a radial nerve type motor response promoted reproducible and remarkable ultrasound spread characteristics associated with complete sensory block of the 3 cords at 30 minutes.

The needle tip placed at the level of posterior cord under ultrasound guidance is described as the most effective way to obtain single shot successful block in adults, for forearm and hand surgeries.

Continuous catheters were placed in the vicinity of the posterior cord under dual neurostimulation and ultrasound guidance in paediatric patients [24]. A radio-opaque dye was injected into the catheters and 5 min later, the dye spread was evaluated fluoroscopically in the infraclavicular area. Based on this study the authors conclude that continuous infraclavicular catheters can be accurately and effectively placed along the posterior cord exclusively under ultrasound guidance in infants and small children.

Conclusion.

This extensive and exhaustive study of over 5000 cases of infraclavicular blocks from 1994-2017 with neurostimulation guidance agrees to the fact that a single neurostimulation posterior cord in particular is appropriate for local anesthetic injection. The contrast spread (Fig. 23) depicts the spread across the brachial sheath as cephalad as the cervical roots and as caudad as the axillary area. It can be thus claimed that infraclavicular posterior cord neurostimulation is the "Spinal of Upper Limb".

References

1.Whiffler K. Coracoid block—a safe and easy technique. Br J Anaesth 1981;53:845–8.

2. NizarMoayeri, Stevens Renes, Geert-Jan van Geffen, Gerbrand J. Groen Vertical Infraclavicular Brachial Plexus Block : Needle Redirection after elicitation of Elbow Flexion. RegAnesth Pain Med 2009 34 336 -41

3.Sauter AR, Smith HJ, Stubaugh A, Dodgen MS, Klaastad O. Magnetic Resonance Imaging to Define the Anatomical Location Closest to All Three Cords of the Infraclavicular Brachial Plexus. AnesthAnalg 2006;103:1574

4. Wilson JL, Brown DL, Wong GY, et al. Infraclavicular brachial plexus block: Parasagittal anatomy important to the coracoid technique. AnesthAnalg 1998;87:870–3.

5.HarishLecamwasam, James Mayfield, Laura Rosow, Yuchiao Chang, Christopher Carter, and Carl Rosow. Stimulation of the Posterior Cord Predicts Successful Infraclavicular Block. AnesthAnalg 2006;102:1564-1568

6.Sala-Blanch X, Carrera A, Morro R, Llusa M. Interpreting infraclavicular motor responses to neurostimulation of the brachial plexus: from anatomic complexity to clinical evaluation simplicity. RegAnesth Pain Med 2004;29:618–20.

7.Borgeat A, Ekatodramis G, Dumont C. An evaluation of the infraclavicular block via a modified approach of the Raj technique. AnesthAnalg 2001;93:436–41.

8. Sunderland S. The intraneural topography of the radial, median, and ulnar nerves. Brain 1945;68:243-299.

9. Gelberman RH. Operative Nerve Repair and Reconstruction. In ,eds Philadelphia, PA: Lippincott; 1991. p. 1288.

10. Minville V, Fourcade O, Bourdet B, Doherty M, Chassery C, Pourrut JC, Gris C, Eychennes B, Colombani A, Samii K, Bouaziz H. The optimal motor response for infraclavicular brachial plexus block. Anesth Analg. 2007

Feb;104(2):448-51

11. Rodríguez J, Bárcena M, Taboada-Muñiz M, Lagunilla J, Alvarez J. A comparison of single versus multiple injections on the extent of anesthesia with coracoid infraclavicular brachial plexus block. Anesth Analg. 2004 Oct;99(4):1225-30

12.Gaertner E, Estebe JP, Zamfir A, Cuby C, Macaire P. Infraclavicular plexus block: multiple injection versus single injection. RegAnesth Pain Med 2002; 27: 590– 4.

13.Rodriguez J, Barcena M, Lagunilla J, Alvarez J. Increased success rate with infraclavicular brachial plexus block using a dual-injection technique. J Clin Anesth 2004; 16: 251–6.

14. Rodriguez J, Barcena M, Taboada-Muniz M, Lagunilla J, Alvarez J. A comparison of single versus multiple injections on the extent of anesthesia with coracoid infraclavicular brachial plexus block. Anesth Analg 2004; 99: 1225–30.

15. Fuzier R, Fourcade O, Fuzier V, Albert N, Samii K, Olivier M. Double- vs. single-injection infraclavicular plexus block in the emergency setting: higher success rate with lower volume of local anaesthetic. Eur J Anaesthesiol 2006; 23: 271–5.

16. Minville V, N'Guyen L, Chassery C, et al. A modified coracoid approach to infraclavicular brachial plexus blocks using a double-stimulation technique in 300 patients. Anesth Analg 2005;100:263–5.

17.Bloc S, Garnier T, Komly B, Leclerc P, Mercadal L, Morel B, Dhonneur G. Single-stimulation, low-volume infraclavicular plexus block: influence of the evoked distal motor response on success rate. Reg Anesth Pain Med. 2006 Sep-Oct;31(5):433-7.

18.Deleuze A, Gentili ME, Marret E, et al. A comparison of a single stimulation lateral infraclavicular plexus block with a triple stimulation axillary block. Reg Anesth Pain Med 2003;28:89–94.

19. Borgeat A, Ekatodramis G, Dumont C. An evaluation of the infraclavicular block via a modified approach of the Raj technique. Anesth Analg 2001;93:436-41.

20. Desroches J. The infraclavicular brachial plexus block by the coracoid approach is clinically effective: An observational study of 150 patients. Can J Anaesth 2003;50:253-7.

21. Jandard C, Gentili ME, Girard F, Ecoffey C, Heck M, Laxenaire MC, et al. Infraclavicular block with lateral approach and nerve stimulation: Extent of anesthesia and adverse effects. Reg Anesth Pain Med 2002;27:37-42.

22. Rodríguez J, Bárcena M, Alvarez J. Restricted infraclavicular distribution of the local anesthetic solution after infraclavicular brachial plexus block. Reg Anesth Pain Med. 2003 Jan-Feb;28(1):33-6.

23. Bloc S, Garnier T, Komly B, Asfazadourian H, Leclerc P, Mercadal L, Morel B, Dhonneur G. Spread of injectate associated with radial or median nerve-type motor response during infraclavicular brachial-plexus block: an ultrasound evaluation. Reg Anesth Pain Med. 2007 Mar-Apr;32(2):130-5.

24. Ponde V, Shah D, Johari A. Confirmation of local anesthetic distribution by radio-opaque contrast spread after ultrasound guided infraclavicular catheters placed along the posterior cord in children: a prospective analysis. Paediatr Anaesth. 2015 Mar;25(3):253-7.

Conflict of Interest: Nil
Source of Support: None

How to Cite this Article

Diwan S. Evoked responses, contrast imaging techniques and outcomes in infraclavicular blocks. International Journal of Regional Anaesthesia. Jan - April 2018; 1(1):15-22