International Journal of
Regional Anaesthesia

Technical Communication

# Lateral Femoral Cutaneous Nerve Block

Trishul Muniraju[1], Murali Thondebhavi[1]
[1]Department of Anaesthesia and Pain management, Apollo Hospitals, Bangalore, Karnataka, India.

## Abstract
The Lateral Femoral Cutaneous Nerve is a sensory nerve with a lot of anatomical variations. This article reviews the latest updates in defining the anatomy of the lateral femoral cutaneous nerve. By understanding the anatomical variations and the presence of a lateral femoral cutaneous nerve canal it is easier to locate the nerve under sonography and improve the accuracy of blocks. This nerve block is important in both acute post-operative pain and chronic pain condition, also known as Meralgia paresthetica.
**Keywords:** Meralgia paresthetica, LFCN canal, LFCN Anatomy

## Introduction
Lateral Femoral Cutaneous Nerve (LFCN) is a branch of the lumbosacral plexus and anaesthesiologists are involved in blocking this nerve either for perioperative reason or in the management of chronic pain. The objective of this article is to provide a narrative review of the anatomy of the nerve, indications and technique of the block.

## Anatomical considerations
The lateral femoral cutaneous nerve is a purely sensory and discrete nerve arising from lumbar plexus, the dorsal divisions of the ventral rami of L2 and L3 spinal nerves, placed in the Psoas compartment formed between the Psoas and the Quadratus lumborum muscles. Rarely, it is also observed to arise from L1 and L2 or L2 alone.

The nerve runs downwards and laterally towards the Anterior Superior Iliac Spine (ASIS) overlaying the Iliacus muscle and emerges from beneath the Inguinal ligament 0.1cm to 6.2 cm medial to the ASIS [2]. The nerve is traversed by the deep circumflex iliac vessels which runs parallel to the inguinal ligament. From here the nerve exits the pelvis and enters a canal formed by the posterior lamina of the Fascia Iliaca, the Fascia lata and the Fascia of the Sartorius muscle known as the LFCN canal [1] which runs downwards and medially over the Sartorius muscle.

The nerve pierces the Fascia Lata and enters the subcutaneous tissue where it divides, at 1.9 cm to 5.0 cm from the ASIS, into two branches, the Gluteal and Femoral branch respectively.

The femoral branch crosses the anterior border of Tensor Fascia Lata and runs downwards and laterally, in its course it branches and supplies the lower lateral skin over the thigh and few of the fibres merge with the anterior cutaneous branches of the femoral nerve and the infrapatellar branches of the saphenous nerve to form the Peri-patellar plexus.

The Gluteal branch runs more laterally and upwards to supply the lateral part of mid-thigh, the skin over the greater trochanter and also the gluteal region [2]. Nevertheless, the sensory distribution of the LFCN is ill-defined and may vary in different individuals. The LFCN has also been observed to have trifurcations and quadrifurcations.

**Address of Correspondence**
Dr. Trishul Muniraju,
Senior Registrar, Department of Anaesthesia and Pain management, Apollo Hospitals, Bangalore, Karnataka, India.
E-mail: dr3shul@gmail.com

Submitted: 21/10/2021; Reviewed: 15/11/2021; Accepted: 12/12/2021; Published: 10/01/2022
DOI: 10.13107/ijra.2022.v03i01.049 | www.ijrajournal.com |

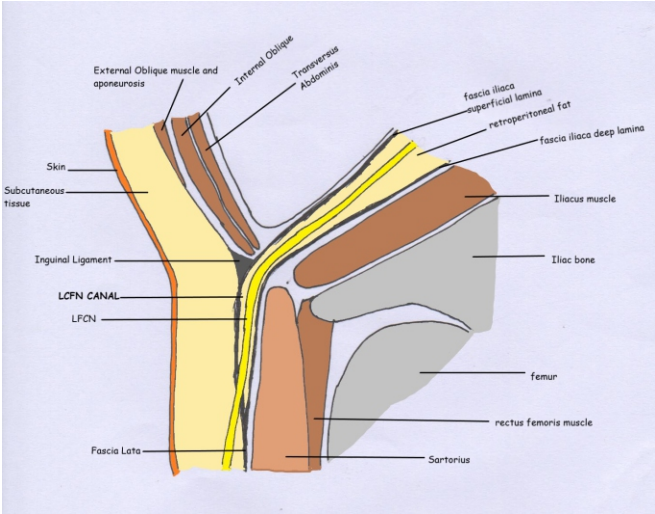


**Figure 1:** Diagrammatic representation of The LFCN Canal. Adapted from Hanna A. The lateral femoral cutaneous nerve canal. J Neurosurg. 2017; 126:972-978.

**Variations in anatomical course of the LFCN** [3]

Seven types of exits of the LFCN from the pelvis has been described so far.

Type 1: medial to the ASIS, under the inguinal ligament. This is the most common type of exit.

Type 2: through the inguinal ligament.

Type 3: over the inguinal ligament.

Type 4: over the ASIS.

Type 5: lateral to the ASIS.

Type 6: through the ASIS.

Type 7: through the Sartorius.

**Lateral Femoral Cutaneous nerve block**

**Indications**

**Perioperative**

- Post-operative Pain management in patients who undergo split skin graft harvesting from lateral aspect of thigh and in Hip joint Arthroplasty.
- Muscle biopsy from lateral aspect of thigh.

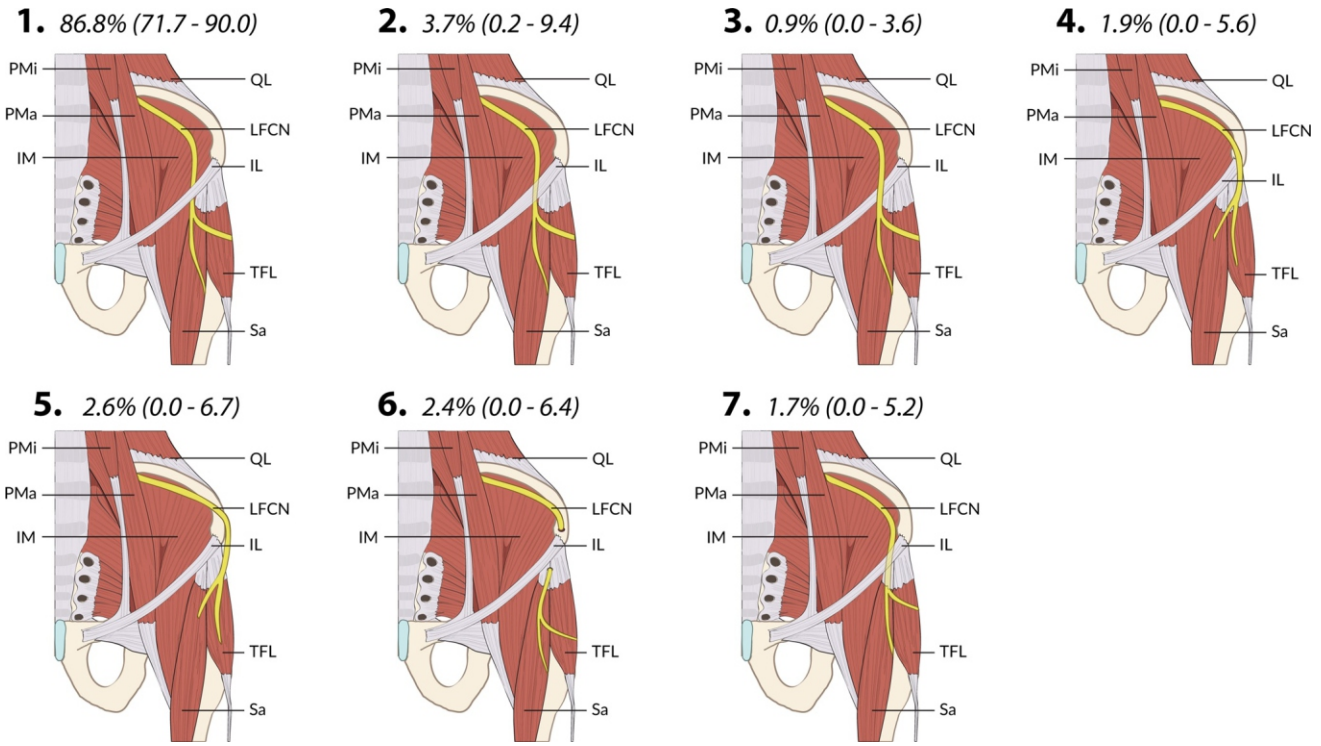


**Figure 2:** Types of exits of the lateral femoral cutaneous nerve from the pelvis with calculated pooled prevalence. PMa psoas major, PMi psoas minor, IM iliacus muscle, Sa sartorius, TFL tensor fasciae latae, IL inguinal ligament, LFCN lateral femoral cutaneous nerve, ASIS anterior superior iliac spine, QL quadratus lumborum. Reproduced with Permission: Tomaszewski KA, Popieluszko P, Henry BM, Roy J, Sanna B, Kijek MR, et al. The surgical anatomy of the lateral femoral cutaneous nerve in the inguinal region: A meta-analysis. Hernia 2016; 20:649-657.

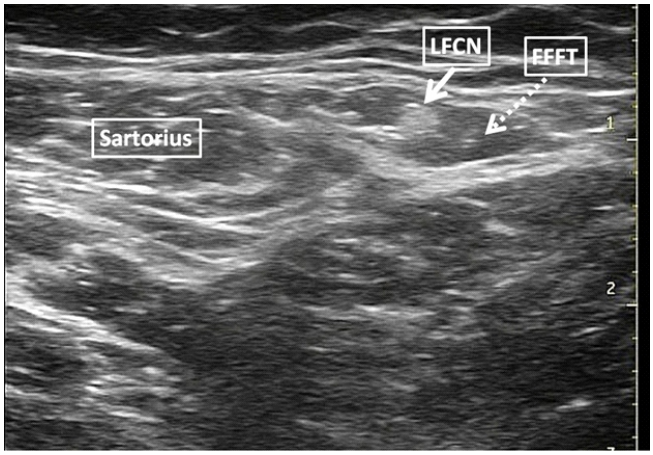


**Figure 3**: Sonographic anatomy showing The LFCN, the LFCN canal (Fat-Filled Flat Tunnel, FFFT).

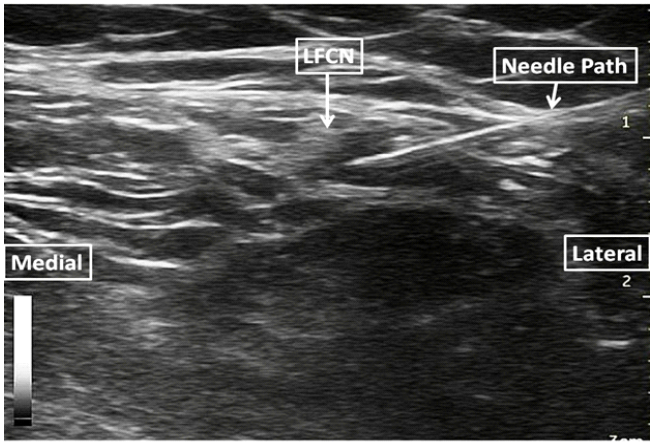


**Figure 4**: Sonographic image showing the needle path and needle placement adjacent the LFCN.

**Chronic pain**

Meralgia Paraesthetica (MP) is a painful mononeuropathy. It is a condition arising in the LFCN and presents with unpleasant sensations or/and pain in the anterolateral aspect of the thigh.

**Techniques for LFCN Block**

**Landmark Technique**

The traditional approach of LFCN block is based on anatomical landmarks. With the patient laying in supine position the needle is inserted 2.5 cm medial to ASIS caudal to the inguinal ligament. The end point for the needle position is determined by a 'pop' sensation felt through the fascial layer or by a fan wise injection technique [4]. Approximately 5 to 10 ml of local anaesthetic is injected.

Due to the anatomical variability in the course of the nerve, the block success rate was suggested to be as low as 40% [4]. Use of peripheral nerve locator increases the success rate of the block at the price of patient discomfort.

**Ultrasound technique**

Patient is placed in a supine position for the block and the ASIS and inguinal ligament are marked. A high frequency linear probe is used to visualise the hyper-echoiec ASIS. The probe is oriented in the long axis of the inguinal ligament and moved distally towards the thigh. The Sartorius muscle is identified as an inverted triangle structure arising from the ASIS. The course of the nerve lies lateral and superior to the Sartorius muscle and is seen either as a hyper-echoiec or hypo-echoeic structure in the plane between the tensor fascia lata and Sartorius muscle coursing in a fat-filled flat tunnel distal to ASIS [5]. The nerve can be seen enlarged or swollen in patients with severe symptoms of MP. The practice of dynamic scanning in this area helps identify the nerve with ease.

Once the nerve is identified, the needle is advanced in strict adherence to sterile technique either in an in-plane (from lateral to medial) or an out-of-plane technique. Approximately 5 to 10 ml of local anaesthetic is injected.

**Conclusion**

LFCN block is an important block to be available in the armamentarium of a practising anaesthesiologist for its utility in the pain management of perioperative population and patients with Meralgia Parasthetica.

**Declaration of patient consent:** The authors certify that they have obtained all appropriate patient consent forms. In the form, the patient has given his consent for his images and other clinical information to be reported in the Journal. The patient understands that his name and initials will not be published, and due efforts will be made to conceal his identity, but anonymity cannot be guaranteed.

**Conflict of interest:** Nil **Source of support:** None

# References

1. Hanna A. The lateral femoral cutaneous nerve canal. J Neurosurg. 2017; 126:972-978.

2. Williams A. 2005. Pelvic girdle and lower limb. In: Standring S, editor.Gray's Anatomy: The Anatomical Basis of Clinical Practice. 39th Ed. Philadelphia, PA: Churchill Livingstone. p 1399–1547

3. Tomaszewski KA, Popieluszko P, Henry BM, Roy J, Sanna B, Kijek MR, et al. The surgical anatomy of the lateral femoral cutaneous nerve in the inguinal region: A meta-analysis. Hernia 2016; 20:649-657.

4. Shannon J, Lang SA, Yip RW. Lateral femoral cutaneous nerve block revisited: a nerve stimulator technique. Reg Anesth. 1995; 20:100-104.

5. Ng I, Vaghadia H, Choi PT, Helmy N. Ultrasound imaging accurately identifies the lateral femoral cutaneous nerve. Anesth Analg. 2008; 107:1070-1074.

**How to cite this article: Muniraju T, Thondebhavi M | Lateral Femoral Cutaneous Nerve Block | International Journal of Regional Anaesthesia | January-June 2022; 3(1): 19-22.**