International Journal of
Regional Anaesthesia

Original Article

Prospective Comparative Double-Blind Study on Ultrasound-Guided Pericapsular Nerve Group Block Versus Suprainguinal Fascia Iliaca Block for Perioperative Analgesia in Traumatic Hip Surgeries

Chetana Bhalerao[1], Ujjwalraj Dudhedia[1]

[1]Department of Anaesthesia, Dr. L.H. Hiranandani Hospital Powai, Mumbai, Maharashtra, India.

Abstract

Background: Severe pain in hip fractures limits ideal positioning for spinal anaesthesia. We evaluated the analgesic efficacy of ultrasound-guided pericapsular nerve group block (PENG) and suprainguinal fascia iliaca block (SIFI) for positioning and postoperative pain relief in hip surgeries.

Methods: A prospective, randomized, double-blind study including 30 patients aged 30-90 years of either sex, American Society of Anesthesiologists'-physical status score I to II undergoing traumatic hip surgeries were divided into two groups. Each group was administered 20 ml bupivacaine 0.25% + 10 ml lignocaine 1%. Vitals and visual analogue scale (VAS) score pre-block, 10 mins post-block, after shifting to operation theatre and after positioning; at rest, and after straight leg raise (SLR) and quadriceps muscle strength were noted. The remaining aspects of perioperative care, including subarachnoid block and rescue analgesic techniques were standardized. Time to request first rescue analgesia, duration of block, and incidence of nausea was noted. Statistical analysis done using the Student t test, Chi-Square test.

Results: VAS scores in both groups 10 mins post block at rest, after SLR, and after positioning were comparable. The drop in VAS score although statistically insignificant was more in the PENG group. The motor blockade in SIFI was significantly higher compared to the PENG group (p-0.002). Duration of analgesia with SIFI 551.9 (±56.2) min was longer than PENG block 400.4 (±62.8) min (p=0.0005%). No significant difference between the groups to demographics, hemodynamic parameters, rescue analgesia and incidence of nausea.

Conclusion: PENG block provides superior and faster analgesia with potentially motor sparing effect compared to SIFI block whereas SIFI provides longer duration of analgesia.

Keywords: Analgesia, Pain, Regional Anaesthesia, Ultrasonography

Introduction

Hip fracture is a common orthopedic emergency in the elderly and requires surgical reduction and fixation as a definitive treatment in most patients. Spinal and combined spinal epidural anaesthesia is most commonly used anaesthesia techniques for the surgical repair of hip fractures. Severe pain associated with these fractures often makes it difficult for positioning of spinal and epidural anaesthesia.

Various regional analgesic techniques, including femoral nerve (FN) block, fascia iliaca block (FIB), and three-in-one FN block are popular analgesic strategies, mainly due to their opioid-sparing effects and reduction in opioid-related adverse effects [1-4]. Analgesia provided by these blocks is incomplete due to the sparing of articular branches of the femoral nerve and accessory obturator nerve [5, 6]. Recently the (Pericapsular Nerve Group (PENG) block which blocks the articular branches of nerves supplying the hip has been described as an effective mode of analgesia in hip fracture patients. Suprainguinal fascia iliaca block (SIFI) has become an approved modality [17, 18] whereas PENG block is a newer modality of analgesia in hip fracture.

Address of Correspondence
Dr. Chetana Vitthal Bhalerao,
Department of Anaesthesia, Dr. L.H. Hiranandani Hospital Powai, Mumbai, Maharashtra, India.
E-mail: chetana.bhalerao999@gmail.com

Submitted: February 11-10-2022; Reviewed: 07-11-2022; Accepted: 16-02-2023; Published: 10-05-2023

DOI: https://doi.org/10.13107/ijra.2023.v04i01.069 | www.ijrajournal.com |

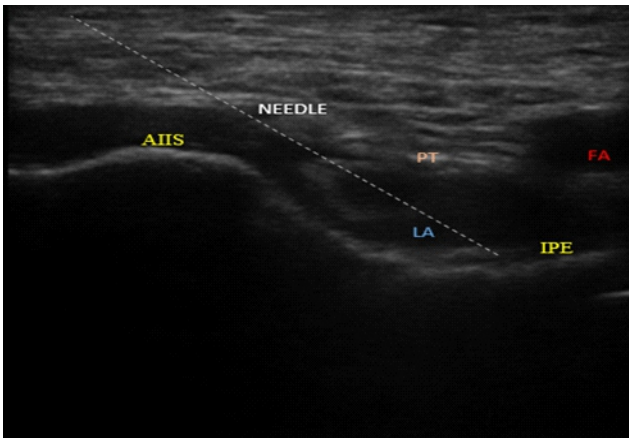

Figure 1: Sonoanatomy of PENG block, AIIS -anterior inferior iliac spine, PT-psoas tendon, IPE-iliopubic eminence, LA-local anaesthetic, FA-femoral artery

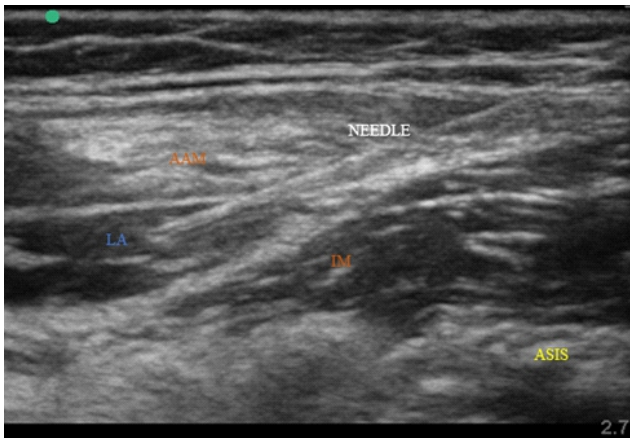

Figure 2: Sonoanatomy of SIFI, AAM – anterior abdominal muscles, IM – Iliacus muscle, ASIS- anterior superior iliac spine, LA- local anaesthetic

FIB involves a block of the femoral and the lateral femoral cutaneous nerve (LFCN) and has been reported to be an effective analgesic technique for hip surgery [7]. Due to the branching of LFCN proximal to the anterior superior iliac spine (ASIS), conventional FIB provides inconsistent blockade of LFCN. However, the newly described ultrasound-guided FIB by the supra-inguinal approach, superior to the inguinal ligament, was reported to block both the femoral and the LFCN completely [8].

There is no substantial comparison research between USG-guided pericapsular nerve block and SIFI block. The purpose of this study is to compare the efficacy of USG-guided PENG block with SIFI block for perioperative analgesia in traumatic hip operations.

Materials and Methods Study Area

This hospital-based, prospective randomised double-blind comparative study was done in the operation theatre complex and recovery room from September 2019 to June 2020 after receiving institutional Ethical committee permission. A total of 30 patients with unilateral hip fracture, American Society of Anesthesiologists'-physical status (ASA-PS) grade I and II, between the ages of 30 and 90 years, were enrolled. Exclusion criteria included patient refusal, coagulopathy, contraindication to spinal anaesthesia, infection at the injection site, and hypersensitivity to local anaesthetics.

Total of 30 patients were randomly divided between two groups A) PENG group B) SIFI group each containing 15 patients. Randomization was computer generated. Double blinding followed i.e., the blocking administrator was blinded for the effect of the block and the observer was blinded for the block administered.

A complete pre-op assessment was carried out. Informed consent was taken. ASA fasting guidelines were followed. In the preoperative room, monitoring of Electrocardiogram, noninvasive blood pressure SpO_2 was done and baseline values were recorded. Sonosite M Turbo USG machine, with linear (6-13mHz) or curvilinear (2-5mHz) probe, was used to identify the anatomy.

Blocks were performed under strict asepsis with the patient in a supine position and using a compatible needle (Stimuplex Ultra 360 ™ - B Braun). Group A received USG guided PENG Block (Figure 1) B received USG-guided SIFI block (Figure 2) with 20ml 0.25% bupivacaine + 10 ml 1% lidocaine, total volume-30cc [19, 20]. The analgesic effect of the block was assessed with the help of VAS score at rest and by performing a straight leg raise test ten mins after giving block, after shifting the patient to operation theatre, and after giving position for spinal.

Thereafter, the patients were made to sit for spinal anaesthesia. Under all aseptic precautions spinal anaesthesia was given with 26 G (BD Quincke's spinal needle-India) with 3 to 3.5 cc (17.5 mg) of heavy hupivacaine. Hemodynamic parameters, including heart rate, SpO_2, and blood pressure were recorded at baseline and at every five minutes to watch for any incidence of hypotension and bradycardia during intraoperative period. The efficacy of analgesia was assessed in postoperative period at 6, 8, 12, 24 hrs using VAS score and the need and time for rescue analgesia was noted. We gave rescue analgesia depending on the patients VAS score. Single analgesic in paracetamol (PCM) 1 gm intravenous (IV) was administered if VAS score was less than four and dual analgesics IV PCM 1 gm (Neomol by Neon laboratories Ltd), IV diclofenac 75 mg (DYNAPAR by Troikka pharmaceuticals Ltd), tramadol 50 mg (Tramazac by Zydus healthcare Ltd) IV if VAS score was more than four. The effect of block was assessed by comparing VAS (Figure 3) at rest and dynamic (SLR to 15°) at baseline, 10 mins post block, after shifting in OT and after positioning. Also, the motor blockade (quadriceps femoris muscle strength) was assessed by extension of fully flexed knee in supine position.

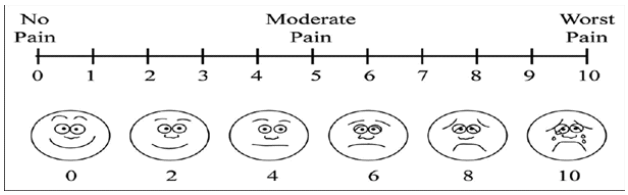

Figure 3: Visual analogue score

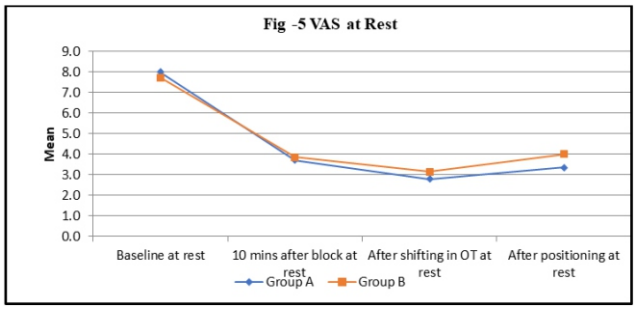

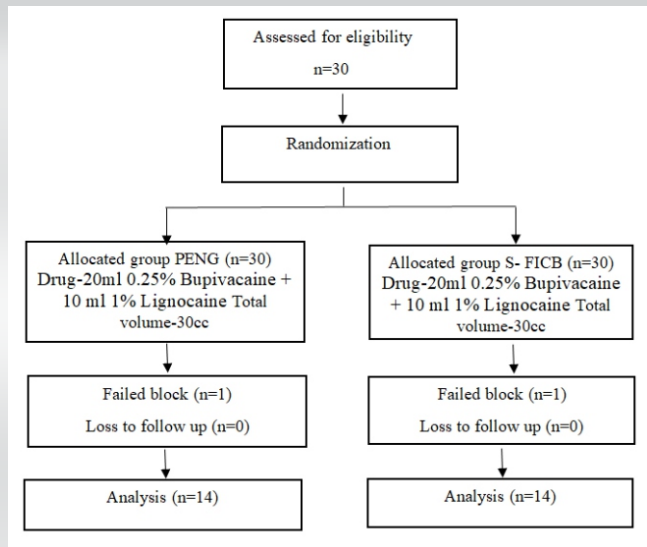

Figure 4: Consort chart

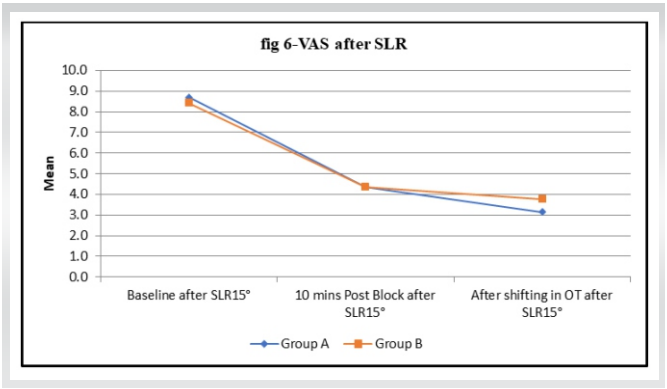

Motor blockade was divided into three grades Grade 0- No motor blockade, Grade 1-motor weakness, Grade 2-complete motor blockade

Primary outcome was to

1. Compare VAS at rest and dynamic (SLR to 15°)
2. Compare incidence and intensity of motor block.

Secondary outcome

1. To measure time to first request analgesia, total dose of analgesic in 24 hr. period
2. Adverse or side effects

Statistical analysis for sample size

No previous study was available which compared VAS score and intensity of motor blockade in patients receiving PENG block and -SIFI block in traumatic hip surgeries. For sample size calculation the proportion of VAS score with PENG block was calculated with the help of pilot study which was 30% and for SIFI block it was considered 50% as there was no previous study calculating the proportion of VAS score. So at 95% confidence interval considering the critical value of the normal distribution at $\alpha/2$ (for a confidence level of 95%) i.e. $Z\alpha/2 = 1.96$, and the critical value of the normal distribution at β (for a power of 80%) i.e. $Z\beta = 0.84$ the sample size calculated was 12 in each group. During study period, we received more cases which we included in the study so the sample size for each group was 15.

The collected data were analyzed with IBM.SPSS statistics software 23.0 Version. To describe about the data descriptive statistics frequency analysis, percentage analysis was used for categorical variables and the mean & S.D were used for continuous variables. To find the significant difference between the bivariate samples in independent groups the Unpaired sample t-test was used. To find the significance in categorical data Chi-Square test was used similarly if the expected cell frequency is less than 5 in 2×2 tables then Fisher's Exact was used. In all the above statistical tools the probability value 0.05 is considered a significant level. (Group A is PENG block whereas group B is SIFI block)

Result

Out of 30 patients, two patients had block failure so a total 28 patients were included in the study. The demographic variables were comparable between the two groups (Table-1). The mean VAS score at rest pre block in PENG and SIFI group was 8(±0.9),7.7(±0.788) respectively, and was comparable (p = 0.284). It dropped to 3.7(±1.3) in PENG and 3.9(±1.7) in SIFI group 10 mins post block (Table-2). VAS scoreafter SLR of 15° (dynamic) preblock was 8.7(±0.6) in PENG, 8.4(±0.5) in SIFI group which dropped to 4.4(±1.6), 4.4(±1.9) respectively 10 mins post block (Table-3). There was approximately 50% reduction in VAS score in both groups 10 mins after institution of block and which dropped further, after shifting to OT to 2.8(±1.6) at rest in PENG and 3.1(±1.9) SIFI group and 3.1(±1.8), 3.8(±2.1)

after SLR respectively. The mean VAS scores after positioning in PENG and SIFI groups were 3.4(±1.9), 4(±1.8).

The quadriceps muscle strength in PENG group was grade 0 in 64.3%, grade 1 in 35.7% and grade 2 in 0% patients whereas in SIFI was grade 0 in 14.3%, grade 1 in 28.6% and grade 2 in 57.1 % patients. (p = 0.002) (Table-4). Thus, motor blockade in SIFI group was significantly higher. Mean duration of block in our study in PENG group was 400.4 (±62.8) min and in SIFI group was 551.9(±56.2) min was statistically significant (p=0.0005%) (Table-5).As rescue analgesia, 64.3% of patients in group A required PCM 500mg, 14.3% required PCM 500 mg + diclofenac 75 mg, and 21.4% required PCM 500mg+tramadol 50mg. In group B, 71.4% of patients needed PCM 500mg, 21.4% needed PCM 500mg, diclofenac 75mg, and 17.9% needed PCM 500mg, tramadol 50mg as rescue analgesia. The P value was 0.535, indicating that the two groups were comparable.

In our study, 14.3% patients in each group had complaint of nausea (p=1) (Table-7). So, groups were comparable. There was no significant difference between incidence of nausea in both groups.

Table-1 -Demographic Data

Parameters	Mean ±SD		p-value
	Group A	Group B	
Age	76 (±8.5)	71 (±14.84).	>0.05
Gender			
Male	57.10%	35.70%	>0.05
Female	42.9%	64.3%.	>0.05
Weight (kg)	78.86 (±9.59)	80 (±10.61).	>0.05
Height (cm)	159.14(±8.47)	160 (±9.04).	>0.05
ASA status			
ASA 1	21.40%	28.6%	>0.05
ASA 2	78.60%	71.4%	>0.05

Table 2-VAS at Rest

VAS	Mean (±SD)		p-value in each group
	Group A	Group B	
Baseline	8.0±0.9	7.7±0.8	0.0005 **
10 mins Post Block	3.7±1.3	3.9±1.7	
After shifting in OT	2.8±1.6	3.1±1.9	
After positioning	3.4±1.9	4.0±1.8	

Table 6. Comparison of rescue analgesia between the groups

			Groups		Total	chi2 – value	p-value
			Group A	Group B			
Total Dose (IV)	PCM 1gm	Count	9	10	19	1.253	0.535 #
		%	64.30%	71.40%	67.90%		
	PCM 1gm +DYNAPA	Count	2	3	5		
		%	14.30%	21.40%	17.90%		
	PCM 1gm+TRAM	Count	3	1	4		
		%	21.40%	7.10%	14.30%		
Total		Count	14	14	28		
		%	100.00%	100.00%	100.00%		

No Statistical Significance at p > 0.05 level

Discussion

In this study, both PENG and SIFI blocks provided effective analgesia with significant reduction in VAS score at rest and positioning, although PENG block provided immediate reduction in VAS score compared to SIFI block in positioning for subarachnoid block (SAB), it was not statistically significant (may be due to small sample size). There was a potential motor-sparing effect in patients receiving PENG block compared to SIFI block. Whereas duration of analgesia and time to request first rescue analgesia was more in SIFI compared to PENG block group.

Hip fractures are common in elderly and is associated with excruciating pain. SAB is most commonly preferred anaesthesia technique for surgical repair of hip fractures for ease of SAB optimal positioning is one of the prerequisites. Severe pain associated with hip fractures makes it difficult in positioning. Amongst various regional anaesthesia techniques recently described PENG block and newer suprainguinal approach of FICB are becoming popular among anaesthesiologists. Short et al [9] recently confirmed that anterior hip capsule is mainly innervated by articular branches of femoral nerve, obturator nerve, and accessory obturator nerve and Articular branches of AON and FN have a greater role in the anterior hip innervation. Giron-Arango L et al [10] in their study found that PENG block consistently

Table 3-VAS after SLR

VAS	Mean (±SD)		p-value in each group
	Group A	Group B	
Baseline	8.7±0.6	8.4±0.5	0.0005 **
10 mins Post Block	4.4±1.1	4.4±1.9	
After shifting in OT	3.1±1.8	3.8±2.1	

Table 4-Quadriceps muscle strength

Grade	Group A	Group B	Total	chi^2 – value	p-value
0	64.30%	14.30%	39.30%		
1	35.70%	28.60%	32.10%		
2	0.00%	57.10%	28.60%		

** Highly Significant at p < 0.01 level

Table 5-Duration of Block

	Groups	Mean	S. D	p-value
Duration of Block	**Group A**	400.4	62.8	0.0005**
	Group B	551.9	56.2	

(Compared by Unpaired t-test)

Table 7: Comparison of incidence of Nausea between Groups

			Groups		Total	chi2 – value	p-value
			Group A	Group B			
Nausea	No	Count	12	12	24	0	1.000 #
		%	85.70%	85.70%	85.70%		
	Yes	Count	2	2	4		
		%	14.30%	14.30%	14.30%		
Total		Count	14	14	28		
		%	100.00%	100.00%	100.00%		

No Statistical Significance at p > 0.05 level

blocks these articular branches by depositing local anesthetic in the musculofascial plane between the Psoas muscle and the superior pubic ramus. It was found to be effective in providing analgesia Fascia iliaca compartment block is considered as other alternative to the femoral and lumbar plexus blocks and involves block of the femoral and the LFCN, and has been reported to be an effective analgesic technique for hip surgery [7]. The conventional fascia iliaca block involves deposition of local anesthetic into the inguinal region and it was found that there was inconsistent blockade of LFCN as it branches proximally at the level of the anterior superior iliac spine [11]. Ultrasound-guided FIB by the supra-inguinal approach, with local anesthetic injection above the inguinal ligament, superficial to the iliacus muscle will block both the femoral and the LFCN. This is because FN and LFCN have a more consistent course at this location. Although SIFI provides analgesia for the hip it may be associated with weakness of quadriceps muscles which affects the early mobilization after surgery. Thus, PENG block has emerged as a reasonable alternative to FICB that produces a predominantly sensory block with greater quadriceps strength preservation and provide excellent pain relief.

In our study there was approximately 50% reduction in VAS score in both groups 10 minutes after institution of block and which dropped further, after shifting to OT to 2.8(±1.6) at rest in PENG and 3.1(±1.9) SIFI group and 3.1(±1.8), 3.8(±2.1) after SLR respectively. The mean VAS scores after positioning in PENG and SIFI group were 3.4(±1.9), 4(±1.8). We administered a block as a part of pre-anaesthesia management so we assessed the VAS score after 10 minutes of administration of the block. We could not get a VAS score of 0 due to the paucity of time but we demonstrated a progressively dropping VAS score till the patient was positioned for spinal anaesthesia in both groups. The drop in VAS although not statistically significant was more in the PENG group.

Giron-Arango L et al [10] in their study evaluated pain scores at rest and with SLR to 15° before and 30 minutes after administration of the PENG block. 4 out of 5 patients had a pain score 0. K Shankar et al [12] in their study between USG-guided PENG block and FIB found that there was a reduction in VAS score 30 minutes after performing the block at rest and during dynamic hip movement as well as during positioning before spinal anaesthesia in both groups which was significantly less in Group P (0.6 ± 0.4) compared to Group F (2.6 ± 1.2). Quality of patient's positioning for spinal anaesthesia was higher in group P (2.348 ± 0.504) versus group F (1.754 ± 0.95) (p = 0.003). Whereas Jadon et al [13] in their study of S-FICB vs PENG block for hip fracture analgesia observed that thirty minutes post-block, the NRS score decreased significantly in PENG group mean (IQR), 6(1) and 9(1.5) to 3(2) and 4(1) and, in S-FICB group 5(1.5) and 8(1) to 4(1) and 5(1) at rest and movement, respectively (P < 0.0001). In a study done by Bhattacharya et al [14], the authors observed that the PENG group had a significantly quicker onset of action (signified by a reduction of pain score by 5) compared to the fascia iliaca group (average of 13.6 minutes and 22 minutes, respectively).

In our study, we observed that patients felt slight discomfort while positioning in both groups which were clinically more in the SIFI group compared to the PENG group (p-value =0.277). Jadon et al [13] stated that during positioning for SA, patients of the PENG group were significantly more comfortable than S-FICB. The mean ease of spinal positioning (EOSP) score was 1.39 and 2.15 in SIFI AND PENG block groups respectively Vermeylen K et al [15] suggested that S-FICB blocks the medial, anterior, and lateral thigh more reliably. They also stated that being a field block the effect of the block depends on the volume of the drug. They used a volume of 40 ml of 0.5 % lignocaine to give S-FICB. Gasanova I et al [16] in their study used 60 ml drug volume. In our study, we used a total volume of 30 ml (20 ml of 0.25 % bupivacaine and +10 ml of 1% lignocaine) in both groups for standardization of protocol and blinding. We feel that a 30 ml volume of the drug was insufficient for the spread of the drug medially in the SIFI group and recommend larger volumes in the SIFI block as used by the above authors. Whereas in the PENG block we found 30 ml of drug volume was able to block the articular branches successfully.

In our study we accessed quadriceps muscle strength 10 mins post block the Quadriceps muscle strength in the PENG group was grade 0 in 64.3%, grade 1 in 35.7%, and grade 2 in 0% of patients whereas in SIFI was grade 0 in 14.3%, grade 1 in 28.6% and grade 2 in 57.1 % patients. (p = 0.002). Thus, motor blockade in the SIFI group was significantly higher in our study.

In our study after SIFI block 8 patients had complete motor blockade, 4 patients had mild motor weakness and only 2 patients had normal quadriceps muscle strength 10 mins post block. This as suggested by Vermeylen K et al [15] could be because S-FICB blocks the anterior thigh more reliably. S-FICB also leads to a more consistent spread in a cranial direction under the fascia iliaca and around the psoas muscle this depending on drug concentration gives more motor blockade in the SIFI group. In the PENG block high articular branches innervating the hip are blocked and Giron-Arango L et al [10] performed a PENG block with 20 mL drug volume. In our study we used 0.25% Bupivacaine 20 ml + 1%

Lignocaine 10 ml so we got mild motor weakness in 5 patients 10 minutes after PENG block.

The mean duration of block in our study in the PENG group was 400.4 (±62.8) min and in the SIFI group was 551.9(±56.2) min was statistically significant (p=0.0005%). So, from our study, it was observed that the SIFI block provided analgesia for a longer duration than the PENG block. S-FICB leads to a more consistent spread in a cranial direction under the fascia iliaca and around the psoas muscle as suggested by Vermeylen K et al [15]. K Shankar et al [12] in their study found that the duration of the PENG block was more than the FICB group. This may be due to their infrainguinal approach of FICB where drug spread will not inevitably lead to a consistent FN block. In a study done by Jadon et al [13] the duration was not significantly different between the S-FICB and PENG groups (the mean in FICB was 11.8 hours and 11.21 hours in PENG) (P = 0.524).

This study has few limitations first the study population in was small and restricted to our hospital. Secondly, we did not evaluate the spread of drug solution in both the blocks either through USG or other modes of imaging. Third we used same volume of drugs in both blocks for standardization whereas both are field blocks requiring different volumes.

Conclusion

To conclude, both PENG and SIFI blocks provided effective analgesia in traumatic hip surgeries but PENG block provided faster and superior analgesia than SIFI block, resulting in easier positioning for SAB,even though it was not statistically significant, whereas SIFI provided longer duration of analgesia for a statistically significant duration. PENG block provided a potential motor sparing effect facilitating early recovery. Both groups had low incidence of complications.

References

[1] Shteynberg A, Riina LH, Glickman LT, Meringolo JN, Simpson RL. Ultrasound guided lateral femoral cutaneous nerve (LFCN) block: safe and simple anesthesia for harvesting skin grafts. Burns. 2013;39: 146-9.

[2] Martins RS, M G Siqueira, Silva FC Jr, Heise CO, Teixeira MJ. A practical approach to the lateral cutaneous nerve of the thigh: an anatomical study. Clin Neurol Neurosurg. 2011; 113:868-71.

[3] Aszmann OC, Dellon ES, Dellon AL. Anatomical course of the lateral femoral cutaneous nerve and its susceptibility to compression and injury. Plast Reconstr Surg. 1997;100: 600-4.

[4] Benezis I, Boutaud B, Leclerc J, Fabre T, Durandeau A. Lateral femoral cutaneous neuropathy and its surgical treatment: a report of 167 cases. Muscle Nerve. 2007;36: 659-63.

[5] Marhofer P, Nasel C, Sitzwohl C, Kapral S. Magnetic resonance imaging of the distribution of local anesthetic during the three-in-one block. Anesth Analg. 2000;90: 119-24.

[6] Swenson JD, Davis JJ, Stream JO, Crim JR, Burks RT, Greis PE. Local anesthetic injection deep to the fascia iliaca at the level of the inguinal ligament: the pattern of distribution and effects on the obturator nerve. J Clin Anesth. 2015;27: 652-7.

[7] Steenberg J, Møller AM. Systematic review of the effects of fascia iliaca compartment block on hip fracture patients before operation. Br J Anaesth. 2018;120: 1368-1380.

[8] Ueshima H, Otake H. Supra-inguinal fascia iliaca block under ultrasound guidance for perioperative analgesia during bipolar hip arthroplasty in a patient with severe cardiovascular compromise: A case report. Medicine. 2018; 97(40).

[9] Short AJ, Barnett JJG, Gofeld M, Baig E, Lam K, Agur AMR, Peng PWH. Anatomic Study of Innervation of the Anterior Hip Capsule: Implication for Image-Guided Intervention. Reg Anesth Pain Med. 2018;43: 186-192.

[10] Girón-Arango L, Peng PWH, Chin KJ, Brull R, Perlas A. Pericapsular Nerve Group (PENG) Block for Hip Fracture. Reg Anesth Pain Med. 2018;43: 859-63.

[11] White S, Stott P. Fascia iliaca block for primary hip arthroplasty. Anaesthesia. 2017;72 :409.

[12] K Shankar, Srinivasan Rangalakshmi, AB Ashwin, et al. Comparative Study of Ultrasound Guided PENG [Pericapsular Nerve Group] Block and FIB [Fascia Iliaca Block] for Positioning and Postoperative Analgesia Prior to Spinal Anaesthesia for Hip Surgeries: Prospective Randomized Comparative Clinical Study. Indian J Anesth Analg.2020;7: 798-803.

[13] Jadon A, Mohsin K, Sahoo RK, Chakraborty S, Sinha N, Bakshi A. Comparison of supra-inguinal fascia iliaca versus pericapsular nerve block for ease of positioning during spinal anaesthesia: A randomised double-blinded trial. Indian J Anaesth. 2021;65: 572-578.

[14] Bhattacharya A, Bhatti T, Haldar M. ESRA19-0539 Pericapsular nerve group block–is it better than the rest for pain relief in fracture neck of femur? Regional Anesthesia and Pain Medicine. 2019; 44(Suppl 1): A116.

[15] Vermeylen K, Desmet M, Leunen I, Soetens F, Neyrinck A, Carens Det al. Supra-inguinal injection for fascia iliaca compartment block results in more consistent spread towards the lumbar plexus than an infra-inguinal injection: a volunteer study. Regional Anesthesia & Pain Medicine. 2019;44: 483-91.

[16] Gasanova I, Alexander JC, Estrera K, Wells J, Sunna M, Minhajuddin A, Joshi GP. Ultrasound-guided suprainguinal fascia iliaca compartment block versus periarticular infiltration for pain management after total hip arthroplasty: a randomized controlled trial. Reg Anesth Pain Med. 2019;44: 206-211.

[17] Ridderikhof ML, De Kruif E, Stevens MF, Baumann HM, Lirk PB, Goslings JC, Hollmann MW. Ultrasound guided supra-inguinal Fascia Iliaca Compartment Blocks in hip fracture patients: An alternative technique. Am J Emerg Med. 2020;38: 231-236.

[18] Bali C, Ozmete O. Supra-inguinal fascia iliaca block in older-old patients for hip fractures: a retrospective study. Braz J Anesthesiol. 2021: S0104-0014(21)00336-5.

[19] Yamada K, Inomata S, Saito S. Minimum effective volume of ropivacaine for ultrasound-guided supra-inguinal fascia iliaca compartment block. Sci Rep. 2020;10: 21859.

[20] Aydin ME, Borulu F, Ates I, Kara S, Ahiskalioglu A. A Novel Indication of Pericapsular Nerve Group (PENG) Block: Surgical Anesthesia for Vein Ligation and Stripping. J Cardiothorac Vasc Anesth. 2020;34: 843-845.

Declaration of patient consent: The authors certify that they have obtained all appropriate patient consent forms. In the form, the patient has given his/her consent for his/her images and other clinical information to be reported in the Journal. The patient understands that his/her name and initials will not be published, and due efforts will be made to conceal his/her identity, but anonymity cannot be guaranteed.

Conflict of interest: Nil **Source of support:** None

How to cite this article: Bhalerao C, Dudhedia U | Prospective Comparative Double-Blind Study on Ultrasound-Guided Pericapsular Nerve Group Block Versus Suprainguinal Fascia Iliaca Block for Perioperative Analgesia in Traumatic Hip Surgeries | International Journal of Regional Anaesthesia | January-June 2023; 4(1): 13-19 | DOI: https://doi.org/10.13107/ijra.2023.v04i01.069